

# The Use of Dorsal Ulnar Artery Flap in Coverage of Wrist Defects

Wael H. Mahmoud, M.D. and Yasser El Hawary, M.D.

The Department of Plastic and Reconstructive Surgery, Faculty of Medicine, Tanta University

## ABSTRACT

**Background:** Soft tissue repair of complicated wrist defects with exposure of the underlying vital structures often present an awkward problem to the reconstructive surgeons. Various flap modalities have been used to resurface of such defects; each of them has its merits and demerits. This study aimed to evaluate the efficiency of "dorsal ulnar artery fasciocutaneous island flap" in reconstruction of wrist soft tissue defects.

**Patients and Methods:** A prospective study was conducted between Sep. 2013 and Sep. 2015 of 13 patients (11 male, 2 female), with post-traumatic soft tissue defects at the volar aspect of the wrist, with mean age of 28.5 years, underwent dorsal ulnar artery fasciocutaneous island flap. The flap size ranged from 7x2.5 to 15x6cm (mean- 9.7x4.2cm). The donor sites were closed primarily in 5 cases and skin grafted in 8 cases.

**Results:** Flap survival was excellent, except for one case with marginal superficial flap necrosis and it was managed conservatively. All the donor and recipient sites were healed uneventfully. After an average follow-up period of 7.2 months, the mean patients' subjective assessment was 8.2 (good) and most patients were satisfied about the functional recovery and the aesthetic appearance of the donor and recipient sites.

**Conclusion:** We can conclude that the dorsal ulnar artery flap is an effective one stage procedure providing good and reliable skin cover with a robust blood supply for small to medium sized defects around the wrist. It facilitates functional restoration with minimal donor site morbidity.

**Key Words:** Wrist soft tissue defects – Dorsal ulnar artery flap – Reconstruction – Dorsal ulnar artery.

## INTRODUCTION

The wrist is considered as a junctional zone through which most of vital structures of the hand pass. This area has also a significant role in hand functions [1]. From this point, reconstruction of complex wrist defects with exposure of underlying structures represents a challenge to plastic surgeons and often requires durable and pliable tissues to preserve the hand functions and to protect its vital structures [2].

Flaps have some superiority over skin grafts such as the chance to provide a tissue that can grow normally without contraction and the possibility for late reconstruction of the underlying vital structures as well as immediate coverage [3]. The need for flap cover can be met either by a local, regional, distant or free flap. Local and regional flaps are more convenient than the other options, as they offer a relatively short operative and hospitalization times, spare distant donor sites for further reconstruction, don't need for sophisticated microsurgical procedures and don't interfere with the patient's physiotherapy or daily activities [4].

The dorsal ulnar artery flap or the dorsoulnar forearm flap based on the dorsal branch of the ulnar artery (DUA), has been first reported by Becker and Gilbert in 1988 [5]. The ulnar artery gives off the DUA between 2 and 4cm proximal to the pisiform bone. The DUA has a diameter of 1-1.3mm, passes medially beneath the flexor carpi ulnaris (FCU) tendon and after 3cm of a common trunk; it gives off 3 collateral branches [6]. The proximal muscular branch to the FCU muscle, the distal osseus branch is the pisiform artery and the medial branch is a fasciocutaneous branch [7] (Fig. 1).

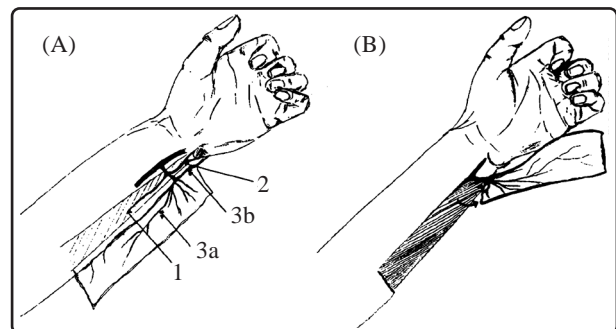


Fig. (1): Dorsal ulnar artery flap. (A) Anatomy of the dorsal ulnar artery: 1, muscular branch; 2, osseous branch to the pisiform; 3, cutaneous branches (a, ascending and b, descending). (B) Elevation of the flap [7].

The fasciocutaneous branch divides into ascending and descending branches on the inferior surface of the FCU. The ascending branch runs between the posterior border of the FCU and the ulnar crest, divides into numerous ramifications providing the vascularization of a large area of skin on the ulnar side of the forearm (9-20cm long x 5-10cm wide), while the descending branch runs distally and then anastomoses with the dorsal carpal arch.

The DUA has two venae comitantes represent the venous drainage of the flap [8]. The dorsal ulnar artery flap has been used for reconstruction of the wrist region without the necessity to sacrifice of a major artery [6,9]. This flap is quite useful as a fasciocutaneous or a fascial fat flap [10]. The fasciocutaneous flap can be raised either with a cutaneous bridge, or as a true island flap [11]. This study was undertaken to evaluate the efficiency of "dorsal ulnar artery fasciocutaneous island flap" in reconstruction of wrist soft tissue defects.

## MATERIAL AND METHODS

Between September 2013 and September 2015, thirteen patients with post-traumatic soft tissue defects at the volar aspect of the wrist underwent dorsal ulnar artery fasciocutaneous island flap at the Department of Plastic and Reconstructive Surgery, Tanta University Hospital. Eleven patients were male and two patients were female, ages ranging from 16 to 40 years (mean, 28.5 years). Among these patients, nine cases had acute injury with skin loss and four had skin necrosis after trauma. Tendon and nerve injuries accompanied the soft tissue loss in four patients.

After approval of the Ethics committee at Tanta Faculty of Medicine, all patients were subjected to full history taking, clinical, radiological and Doppler examination to evaluate the extent of the missing tissues, to assess skeletal affection and for localization of the vascular pedicle respectively. Informed consent was taken from all patients.

### *Surgical technique:*

A line was drawn between the medial epicondyle of the humerus and the pisiform indicating the axis of the flap (Fig. 2). The distal margin of the flap must not exceed the distal wrist crease to prevent scar formation on the joint.

About 2-4cm proximal from the pisiform and on the ulnar side of the distal forearm the site of the dorsal ulnar artery was detected and marked with the aid of Doppler probe preoperatively. All operations were done under general anaesthesia with pneumatic tourniquet control and a loupe magnification.

After debridement, concomitant tendon and nerve injuries were repaired primarily. The flap was outlined over the ulnar aspect of the forearm according to the size of the defect. The distance between the pivot point of the pedicle and the proximal edge of the flap was planned to be 25% longer than the distance between the pivot point and the defect.

We started dissection from proximal to distal on the ulnar side of the forearm and wrist. The flap was raised as a fasciocutaneous island flap (Fig. 3). The FCU was retracted laterally to expose the flap's pedicle that was located 2-5cm proximal to the pisiform. Care was paid to preserve the dorsal branch of ulnar nerve while identifying and dissection of the DUA from its origin from the ulnar artery to allow 180° rotation of the flap. The intervening skin segment between the flap's pedicle and the defect was laid open. As the flap was nourished by the antegrade flow (ascending branch), the tourniquet was then released and the perfusion of the flap was confirmed. Hemostasis was done and the flap was turned over distally to cover the defect (Fig. 4). The flap donor site, up to 4cm in width, was closed primarily by undermining of the surrounding skin, while larger defects were skin grafted (Fig. 5). After suturing was complete, a gauze dressing was applied.

### *Post-operative care:*

The hand was kept elevated for 5 days to improve the venous return and was immobilized in the neutral position using dorsal splint for 2 weeks. The operation was followed by a period of physiotherapy for about 2-3 months. The occurrence of the complications was carefully observed as flap necrosis, bleeding, infection, graft loss and donor site morbidity. Patients' subjective satisfaction was assessed as regards to the functional recovery and the aesthetic appearance of the recipient and donor sites, they were evaluated using the visual analog scale ranging from zero (completely disappointed) to ten (completely satisfied) and were divided into 3 classes (poor, 1-4; fair, 5-7; good, 8-10).

## RESULTS

In two years, thirteen dorsal ulnar artery fasciocutaneous island flaps were used for coverage of post-traumatic volar skin defects of the wrist in 13 patients with mean age of 28.5 years. The summarized data about the patients and the outcomes are presented in (Table 1).

All operations were successful. The average flap length was 9.7cm, ranging from 7 to 15cm.

The average flap width was 4.2cm, ranging from 2.5 to 6cm. Flap survival was excellent, except for one case with marginal superficial flap necrosis most probably due to venous congestion and it was managed conservatively and healed by 2<sup>nd</sup>ry intention. The donor sites in five cases were closed primarily and in eight cases that were  $\geq 4$ cm in width were grafted. All the donor and recipient sites were healed uneventfully.

After an average follow-up period of 7.2 months (range from 3 to 12 months), the flap showed good durability and elasticity and there was good movement of the wrist and fingers in both extension and flexion. The aesthetic appearance of the recipient and donor sites was acceptable, without any noticeable contour abnormalities. The mean patients' subjective satisfaction score was 8.2 (range from 5 to 10).

Table (1): Patients' data and outcomes.

Case no.	Age (yr)/sex	Flap size (cm)	Donor site closure	Complications	Patient subjective assessment	Follow-up
1	25/M	11X5	STSG	No	8	9
2	23/M	12X6	STSG	No	8	4
3	27/M	15X6	STSG	Marginal superior necrosis	7	11
4	35/M	7X3	Primary	No	10	3
5	28/F	8X3.5	Primary	No	8	8
6	40/M	10X5	STSG	No	7	5
7	16/M	8X5	STSG	No	9	8
8	30/M	7X2.5	Primary	No	10	6
9	31/F	10X4	STSG	No	5	12
10	38/M	11X4	STSG	No	8	12
11	23/M	8X3.5	Primary	No	9	6
12	36/M	10X4	STSG	No	7	5
13	18/M	9X3	Primary	No	10	5

(STSG): Split thickness skin graft. (M): Male. (F): Female.

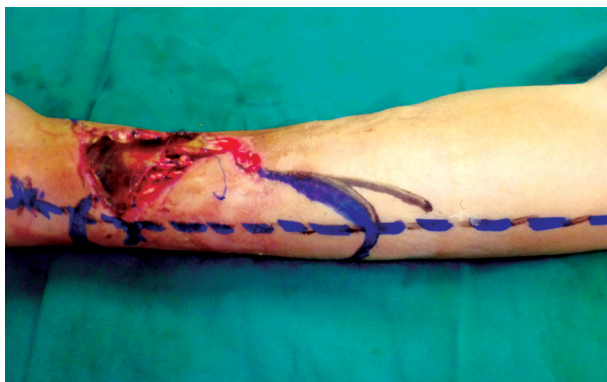


Fig. (2): (Pre-operative marking) A line was drawn between the medial epicondyle of the humerus and the pisiform indicating the axis of the flap.

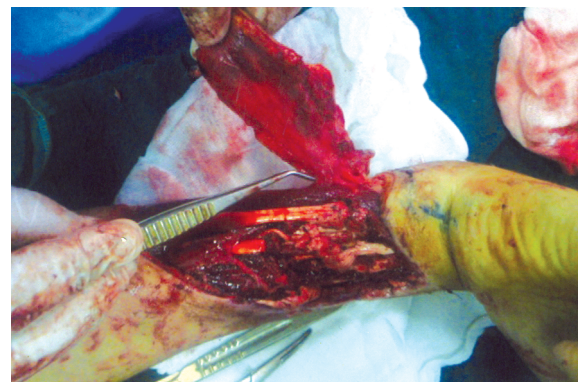


Fig. (3): Complete elevation of the flap to until the vascular pedicle.

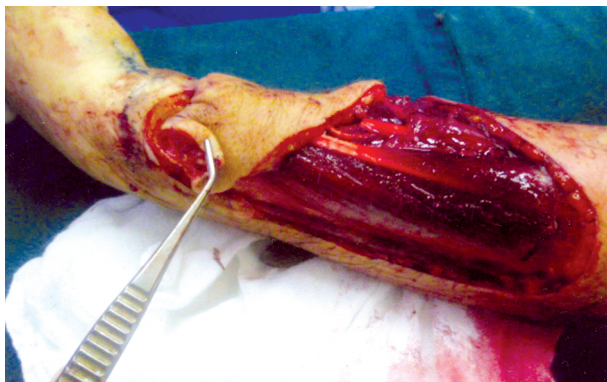


Fig. (4): Transposition of the flap to cover the defect after being completely islanded.

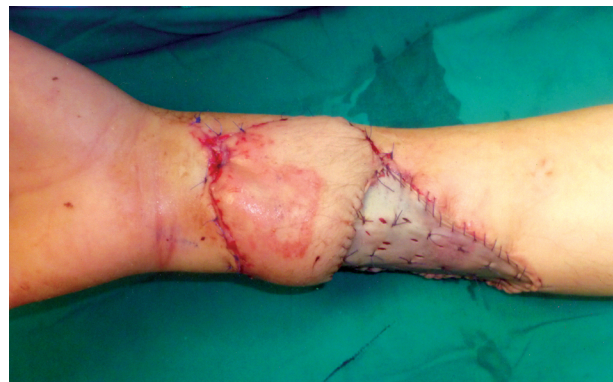

Fig. (5): The donor site was covered by STSG.



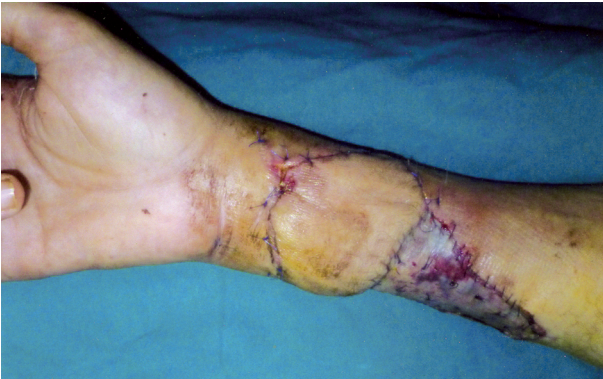

Fig. (6): Early post-operative picture shows sound healing of both donor and recipient sites.

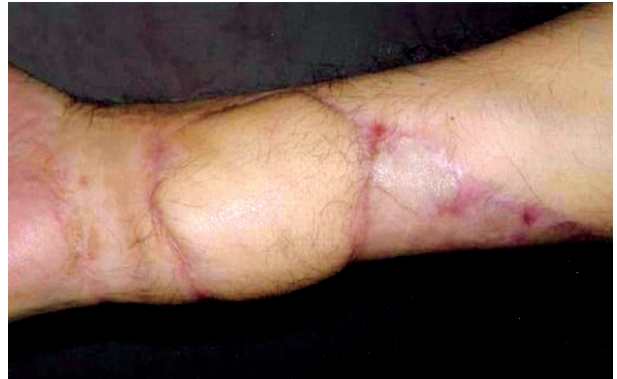

Fig. (7): Late post-operative picture shows good aesthetic results of both donor and recipient sites.

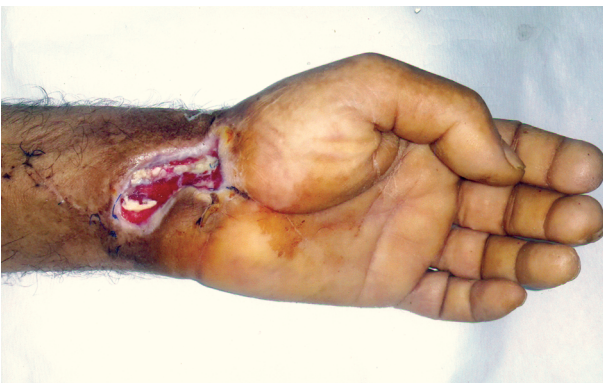

Fig. (8): Exposure of flexor tendons after debridement of necrotic skin.

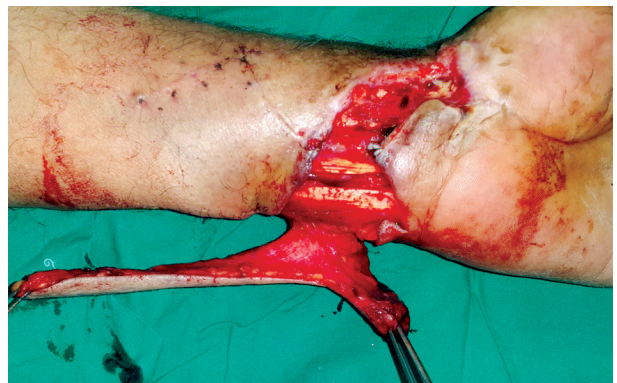

Fig. (9): The flap is completely islanded.

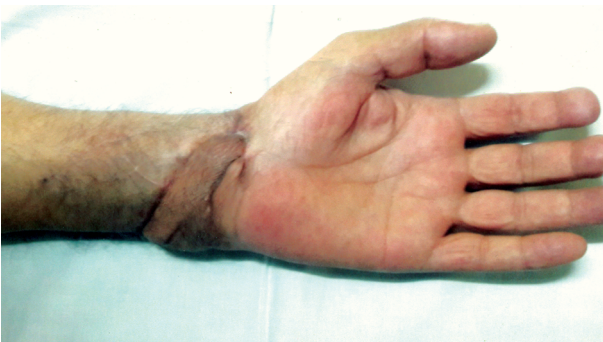

Fig. (10): Late post-operative picture. (Anterior view).

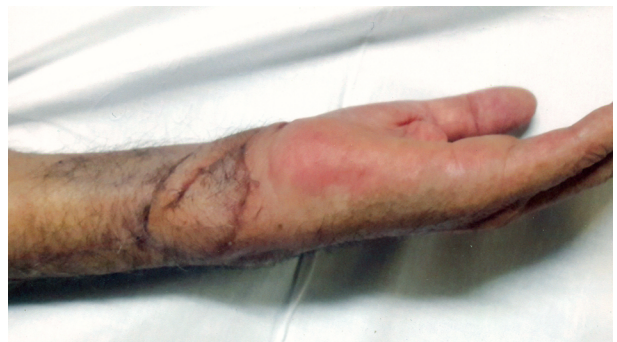

Fig. (11): Late post-operative picture. (Lateral view).

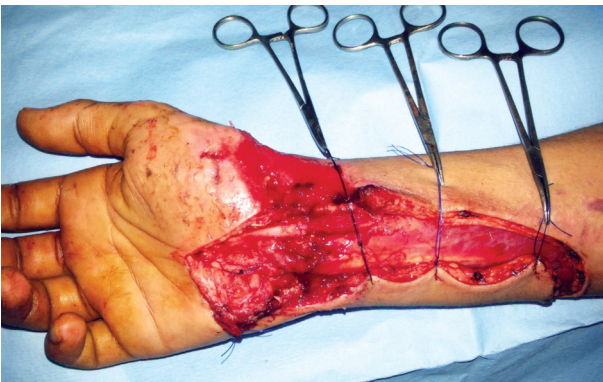

Fig. (12): Post-traumatic loss of the volar wrist skin.

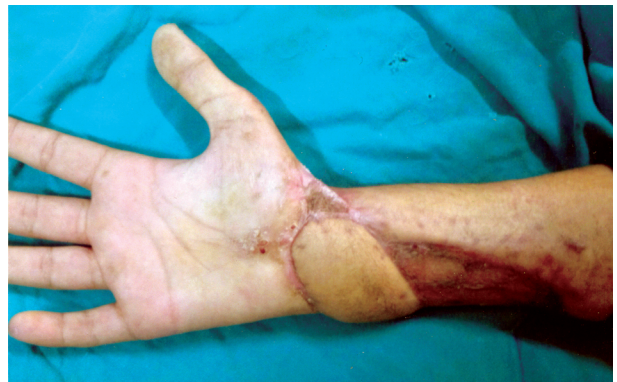

Fig. (13): Late post-operative picture shows good functional and aesthetic results.



## DISCUSSION

Soft tissue defects around the wrist with exposed tendons, nerves, bone and joints are common sequel in hand injuries, for which the reconstruction remains challenging. Many therapeutic modalities have been described to resurface such defects; each of them has its own merits and demerits. The pedicled groin flap [12] has successfully been used as popular distant flap in the literature. However, multiple-stage procedures, long duration of immobilization and being bulking with suboptimal color match are major handicaps. Free flaps [13] offer flexibility in shape and size but are limited with regard to the need for a facility of microsurgery and donor site morbidity.

The posterior interosseus distally based flap [14] has commonly been used in coverage of hand and wrist defects in both adults and children. However, the flap perfusion may be jeopardized in volar wrist defects as the anastomosis between the anterior and posterior interosseus may be injured from trauma and the dissection of the vascular pedicle is frequently tedious and complex. The distally based radial forearm flap [15] and the reverse ulnar artery forearm flap [16] have stood the test of time in reconstruction of such defects. However, sacrifice of major vascular axis and donor site morbidity are major drawbacks. We aimed in this study to evaluate the efficiency of "dorsal ulnar artery fasciocutaneous island flap" in reconstruction of wrist soft tissue defects.

The dorsal ulnar artery flap was first described by Becker and Gilbert [5], based on the DUA for reconstruction of hand and wrist defects. The dorsal ulnar artery (DUA) is quite reliable. In our series, we constantly found the DUA in all our cases.

In agreement with us, the DUA was consistently found by many authors [17,18]. However, Becker and Gilbert [5] noticed the absence of the DUA in 2 of 100 dissections and Amarate et al. [19] observed the absence of the DUA in 3 of 50 dissections. In our study, we used the proximally based flap based on the DUA as the flap's pedicle was long enough to reach all the wrist defects. On the contrary, Bertelli et al. [18] and Karacalar et al. [20] used the distally pedicled dorsoulnar flap to extend the vascular pedicle to reach distal hand defects, by ligating and division the DUA depending on the descending branch of the DUA retrogradely.

Unlike our results, Hlevich-Madjarova et al. [21] noted that the maximum size of the dorsal ulnar artery flap should be 10x5cm. However, we could use flaps as large as 15x6cm. Similarly,

Antonopoulos et al. [2] designed flaps up to 20x9cm which is considered the maximum theoretical limit of the territory supplied by the DUA. Similar to our study, Liu et al. [13] found that donor sites less than 4cm could be closed primarily while larger ones needed to be skin grafted. In other studies [8,22], donor sites up to 5cm could be closed primarily by wide undermining of the surrounding skin.

In this study, one flap developed marginal superficial flap necrosis mostly due to venous congestion and it was managed conservatively. In similar studies, Ulkar et al. [22] encountered partial necrosis in 2 out of 8 cases, Khan et al. [9] observed marginal necrosis in 2 out of 12 cases, Antonopoulos et al. [2] reported superficial necrosis in 2 out of 6 cases due to poor venous drainage when larger flaps were harvested and suggested certain modifications such as to include superficial veins in the pedicle or to anastomose such veins to the dorsal venous arch and Tan et al. [3] supercharged the dorsal ulnar artery flap by anastomosing a branch of the cephalic vein to the antebrachial vein to enhance the venous flow.

This series witnessed that the mean patients' subjective assessment was 8.2 (good) and most patients were satisfied about the functional recovery and the aesthetic appearance of the donor and recipient sites. In other studies, Uygur et al. [23] found that the functional recovery of the hands was good as well as satisfactory cosmetic results of both donor and recipient sites, Abd Al-moktader [8] noticed that although the flap was aesthetically good, the scar formation at the donor site was a true drawback of this technique, Liu et al. [13].

Observed that all the patients returned to pre-surgical functional status after wound healing and all the scars at the donor sites were unnoticeable and Vergara-Amador [24] demonstrated that the donor sites on the forearm ulnar side had a good aesthetic acceptance.

We recommend for a larger clinical study with a longer follow-up period for better evaluation of the functional and aesthetic outcomes of this flap.

*Conclusion:* We can conclude that the dorsal ulnar artery flap is an effective one stage procedure providing good and reliable skin cover with a robust blood supply for small to medium sized defects around the wrist without the sacrifice of a major vascular axis. It facilitates functional restoration with minimal donor site morbidity.

## REFERENCES

- 1- Johnson D.: Wrist and hand. In: Standring S., editor. Gray's anatomy. 40<sup>th</sup> ed. New York: Churchill Livingstone, 857-98, 2008.
- 2- Antonopoulos D., Kang N.V. and Debono R.: Our experience with the use of the dorsal ulnar artery flap in hand and wrist tissue cover. *J. Hand Surg. Br.*, 22: 739-44, 1997.
- 3- Tan O. and Kiliç M.: Supercharged dorsoulnar island flap: A case report and review of the literature. *Acta. Orthop. Traumatol. Turc.*, 45 (1): 53-7, 2011.
- 4- Karki D. and Singh A.K.: The distally-based island ulnar artery perforator flap for wrist defects. *Indian J. Plast. Surg.*, 40: 12-7, 2007.
- 5- Becker C. and Gilbert A.: The ulnar flap - description and applications. *Eur. J. Plast. Surg.*, 11: 79-82, 1988.
- 6- Malko I., Karagoz H., Alp B., et al.: Anatomical evaluation of the dorsal ulnar artery. *Turk J. Med. Sci.*, 42 (1): 167-71, 2012.
- 7- Chao J.D., Huang J.M. and Wiedrich T.A.: Local hand flaps. *J. Hand Surg. Am.*, 1 (1): 25-44, 2001.
- 8- Abd Al-Moktader M.: Superficial Dorsal Ulnar Artery Flap for Hand and Wrist Coverage. *Egypt J. Plast. Reconstr. Surg.*, 34 (2): 219-22, 2010.
- 9- Khan M.M., Yaseen M., Bariar L.M., et al.: Clinical study of dorsal ulnar artery flap in hand reconstruction. *Indian J. Plast. Surg.*, 42 (1): 52-7, 2009.
- 10- Luchetti R., Riccio M., Papini Zorli I., et al.: Protective coverage of the median nerve using fascial, fasciocutaneous or island flaps. *Handchir Mikrochir Plast. Chir.*, 38 (5): 317-30, 2006.
- 11- Galli S., Vignasio A., Simonini G., et al.: Becker's dorsal ulnar flap in hand surgery. *Minerva Ortopedica e Traumatologica*, 50 (2): 63-8, 1999.
- 12- Jokuszies A., Niederbichler A.D., Hirsch N., et al.: The pedicled groin flap for defect closure of the hand. *Oper. Orthop. Traumatol.*, 22 (4): 440-51, 2010.
- 13- Liu J. and Zheng H.: Free distal ulnar artery perforator flaps for the reconstruction of a volar defect in fingers. *J. Plast. Reconstr. Aesthet. Surg.*, 67 (11): 1557-63, 2014.
- 14- Tan O.: Reverse posterior interosseous flap in childhood: a reliable alternative for complex hand defects. *Ann. Plast. Surg.*, 60: 618-22, 2008.
- 15- Otene C.I., Achebe J.U. and IS Ogbonnaya I.S.: The Radial Forearm Flap in reconstruction of upper limb injuries: A case series. *J. West Afr. Coll. Surg.*, 1 (1): 131-44, 2011.
- 16- Grobbelaar A.O. and Harrison D.H.: The Distally Based Ulnar Artery Island Flap in Hand Reconstruction. *J. Hand Surg. Br.*, 22: 204-11, 1997.
- 17- Bertelli J.A. and Houry Z.: Radial and ulnar nerve vascularization in the hand: Anatomical basis of neurocutaneous flaps. *Surg. Radiol. Anat.*, 14: 87-92, 1992.
- 18- Bertelli J.A. and Pagliei A.: The neurocutaneous flap based on the dorsal branches of the ulnar artery and nerve: A new flap for extensive reconstruction of the hand. *Plast. Reconstr. Surg.*, 101: 1537-43, 1998.
- 19- Amarante J.: Pedicle fasciocutaneous and adipofascial flaps. Severe traumatic defects of the upper limb. Dunitz-Taylor and Francis group, 2003.
- 20- Karacalar A. and Ozcan M.: Preliminary report: The distally pedicled dorsoulnar forearm flap for hand reconstruction. *Br. J. Plast. Surg.*, 52: 453-7, 1999.
- 21- Holevich-Madjarova B., Paneva-Holevich E. and Topkarov V.: Island flap supplied by the dorsal branch of the ulnar artery. *Plast Reconstr. Surg.*, 87: 562-6, 1991.
- 22- Ulkür E., Açikel C., Eren F., et al.: Use of dorsal ulnar neurocutaneous island flap in the treatment of chronic postburn palmar contractures. *Burns*, 31: 99-104, 2005.
- 23- Uygur F., Uygur M., Ulkür E., et al.: Versatility of the reverse dorsoulnar fasciocutaneous flap in coverage of hand defects: Clinical experience with 36 cases. *J. Hand Surg.*, 34A: 1327-33, 2009.
- 24- Vergara-Amador E.: The Retrograde Ulnar Dorsal Flap: Surgical Technique and Experience as Island Flap in Coverage of Hand Defects. *Tech Hand Up Extrem Surg.*, 19 (3): 90-4, 2015.